

DEPARTMENT OF  
OTOLARYNGOLOGY-  
HEAD AND NECK SURGERY

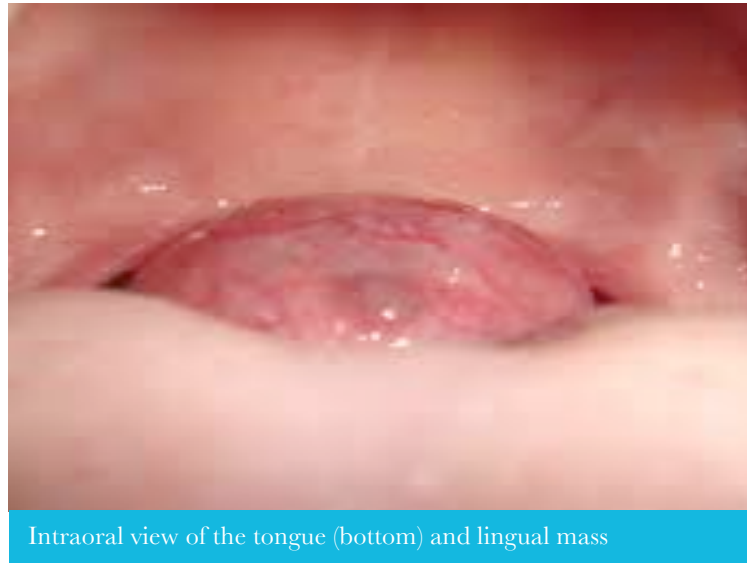

ENT and Allergy  
Associates, LLP

This patient was  
referred by a tri-state  
ENTA physician

## PATIENT SPOTLIGHT

*A twenty-three year old female presents  
with snoring and a hoarse voice*



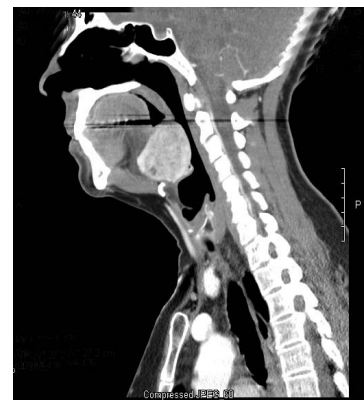### The lingual thyroid increases in the second decade of life.

The lingual thyroid is a form of ectopic thyroid tissue that commonly occurs in the midline of the tongue base. Ectopic thyroid tissue has also been reported in the sublingual, submandibular, prelaryngeal, tracheal, mediastinum, heart, esophagus, diaphragm, and peripharyngeal region. The lingual thyroid occurs more frequently in females and is seen in any age. This infrequent congenital anomaly is often asymptomatic. The lingual thyroid increases in the second

decade and clinical incidence varies between 1:3000 and 1:10,000. Importantly, 75% of cases with lingual thyroid do not have a normal functioning thyroid gland in the neck and lingual thyroid is the only functional thyroid tissue.

The diagnosis of ectopic thyroid can be made through physical examination, ultrasound, CT, and MRI as radiological methods as well as scintigraphy. Computed tomography (Figure below) and MRI make it possible to estimate the gland size and position. The majority of patients require

surgical excision of the symptomatic mass, which can be performed transorally and robotically. In the case of absence of orthotopic thyroid tissue, long-term thyroid hormone replacement will be necessary.



Our shared EHR facilitates a seamless referral process and transfer of medical records with the push of a button

2013

## Pearls

### Sleep Apnea

Lingual thyroid may initially present as sleep apnea. In a young patient, consider the lingual thyroid if the patient is thin and atypical for sleep apnea.

### The CT Scan

The CT scan provides an excellent view of the lingual thyroid and confirms the diagnosis. The enhancement seen with iodine dye helps to confirm the diagnosis.

### Pathology

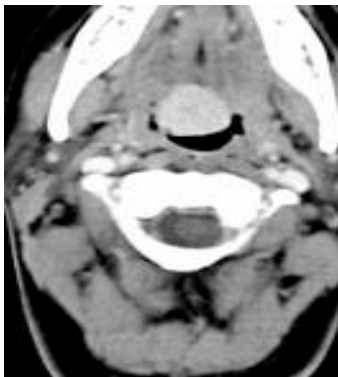
The lingual thyroid is typically well circumscribed. It is excised with minimal bleeding or trauma to the underlying muscle of the tongue.

## Prevalence of Lingual Thyroid

Although on a microscopic level lingual thyroid may be present in 10% of people, clinically relevant rates occur in 1:10,000 to 1:100,000 people. Most patients with lingual thyroids are asymptomatic. The mean age for presentation is 40 years, with bimodal peaks at 12 and 50 years of age.

## Signs and Symptoms

Signs and symptoms of lingual thyroid are typically related to its size and include dysphagia, dysphonia, dyspnea, and rarely hemorrhage. Large masses can present with airway obstruction and stridor. In this patient, the dysphagia was a mass effect, however, the hoarse voice was a result of gastroesophageal reflux secondary to obstructive sleep apnea. The mass created apnea and the negative pressure of inspiration likely resulted in acid reflux.



## Non-Surgical Management

If obstructive symptoms are relatively mild, the best initial treatment is suppressive therapy with Synthroid. TSH suppression may result in reduction of the gland size but dramatic results are rare. We recommend an evaluation by an endocrinologist to monitor and optimize thyroid function. However, if there are obstructive symptoms that do not respond to medical therapy, surgery is indicated.

## Surgical Management

Surgical management of the lingual thyroid can be achieved transorally with a headlight and a Bovie cautery. In this case, we performed the procedure with a transoral robotic technique. This approach provided excellent visualization and hemostasis. Postoperatively, the patient did exceptionally well and was discharged one day after surgery on a soft diet. The reflux, apnea, and dysphagia abated following surgery.

Because the lingual thyroid was the only source of thyroid tissue for this patient, thyroid hormone replacement was started immediately post operatively.

The patient has recovered and is symptom free.

*Eric Genden, MD*

## MOUNT SINAI OTOLARYNGOLGY

Eric M. Genden, MD  
Chairman  
Head and Neck Cancer

William Lawson, MD, DDS  
Vice-Chairman  
Rhinology and Facial Plastics

Kenneth W. Altman, MD, PhD  
Director, Laryngology and  
Professional Voice

Satish Govindaraj, MD  
Director, Endoscopic Skull Base  
Surgery

Fred Y. Lin, MD  
Director, Sleep Surgery

Brett A. Miles, MD, DDS  
Head and Neck Cancer

Joshua D. Rosenberg, MD  
Facial Plastics, Head and Neck  
Cancer

Eric E. Smouha, MD  
Director, Otolaryngology and Neuro-  
Otolaryngology

Marita S. Teng, MD  
Head and Neck Cancer

### Manhattan:

Faculty Practice Associates  
5 East 98th Street, 8th Floor  
New York, NY 10029

Center for Science and  
Medicine  
10 East 102nd St, 3rd Floor  
New York, NY 10029

### Staten Island:

2052 Richmond Road, Suite C  
Staten Island, NY 10306

### Long Island:

325 Park Avenue  
Huntington, NY 11743

### To Refer a Patient:

Call us direct at Physician Access  
Services: 212-241-4983